

F. Ahmadi MD<sup>1</sup>  
 A. Vosough Taghi Dizaj MD<sup>1</sup>  
 Sh. Irani BSc<sup>2</sup>

## Prenatal Diagnosis of Fetal Umbilical Vein Varix in An Intracytoplasmic Sperm Injection Conception: A Case Report

Varix of the umbilical vein is a rare entity. We report a case of fetal intraabdominal umbilical vein varix (FIUV) diagnosed by color Doppler ultrasonography at 24 weeks of gestation. This case had normal ultrasound at 13-19 weeks. No other anomalies were detected in subsequent evaluations by ultrasonography and echocardiography. Eventually the fetus at 30 weeks' gestation was affected by hydrops and Intrauterine Fetal Death occurred at 31 weeks gestation.

**Keywords:** umbilical vein, varix, prenatal ultrasonography

### Introduction

Fetal intra-abdominal umbilical vein varix (FIUV) which is characterized with focal dilatation of the umbilical vein is very uncommon and only a scarce number of cases have been reported in the literature.<sup>1-10</sup> The significance of antenatal detection of umbilical vein varix remains controversial.<sup>1,5,11,12</sup> An earlier study reported an alarmingly high rate of fetal loss: four of nine fetuses with FIUV died in utero.<sup>1</sup> However, more recent case series have shown that FIUV varix may not be associated with poor outcome.<sup>12</sup> In ultrasonography, the typical appearance of FIUV is an ovoid or elongated fluid-filled mass, oriented obliquely in the cephalocaudal direction, between the abdominal wall and the inferior edge of liver.<sup>1</sup> The presence of venous blood flow within the lesion on Doppler velocimetry confirms the diagnosis.

### Case Report

A 34-year-old pregnant woman, gravida 2, para 0, with 7 years of primary infertility, normal karyotype and no history of familial genetic disorders was admitted to Royan Institute (Infertility Clinic & Reproductive Biomedicine Research Center). Her husband had a normal karyotype. After preliminary workup, she underwent the intracytoplasmic sperm injection (ICSI) cycle with conventional protocol (GnRH $\alpha$  / HMG). After 10 to 12 days of embryo transfer, BHCG were tested. At 7 weeks, a single gestational sac with a live fetus was seen.

Sonographic evaluation at 13 weeks confirmed normal fetal anatomy. In routine ultrasound examination at 16 weeks, only the volume of amniotic fluid was a little lower than the normal range, whereas in 19 weeks of gestation the amniotic fluid was within the normal limits. At 24 weeks, a varix with a diameter of 1.3 cm was detected in the extra-hepatic portion of the fetal umbilical vein (Figure 1). Venous flow pattern within the lesion using Doppler velocimetry confirmed the diagnosis (Figure 2). In addition, a fetal echocardiography done at 26 weeks of gestation indicated mild MR (Mitral regurgitation)/TR (Tricuspid

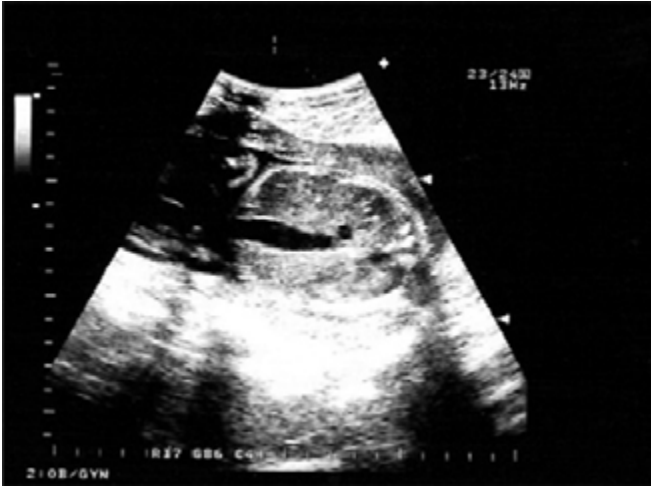1. Assistant Professor of Radiology,  
 Department of Endocrinology and  
 Female Infertility, Royan Institute,  
 Tehran, Iran.

2. Bachelor of Science in Midwifery,  
 Department of Endocrinology and  
 Female Infertility, Royan Institute,  
 Tehran, Iran.

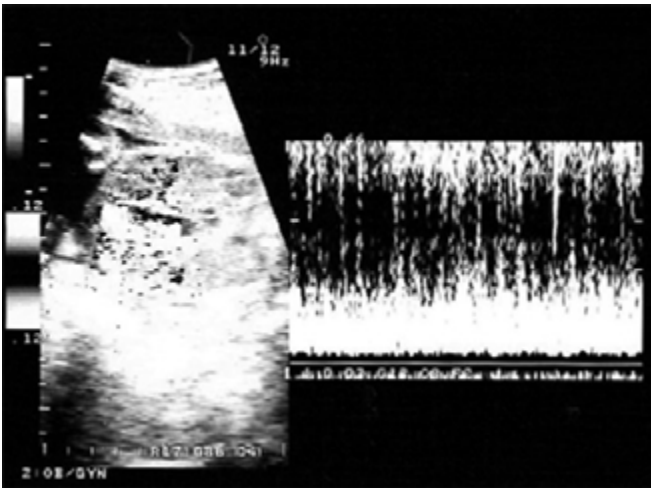
Corresponding Author:  
 Firoozeh Ahmadi  
 Address: Royan Institute, No 36, Simin  
 Alley, Zafaraniyeh, Tehran, Iran.  
 P.O.Box: 19395-4644  
 Tel: +9821-22413790  
 Fax: +9821-22409314  
 Email: f\_ahmadi@royaninstitute.org

Received August 20, 2006;  
 Accepted after revision December 5,  
 2006.

Winter 2007;4:117-119



**Fig 1.** Transabdominal ultrasound shows the increased diameter of the affected umbilical vein.



**Fig 2.** Doppler velocimetry shows venous flow in the varix.

regurgitation) and normal EF (Ejection Fraction) of ventricles.

In weekly follow-ups, signs of severe hydrops — plural and pericardial effusion, fetal ascites, and skin edema appeared at 30 weeks of gestation and intrauterine fetal death (IUFD) ensued at 31 weeks.

## Discussion

Umbilical vein varix is defined as either a focal dilatation of the umbilical vein more than 9mm in diameter, or a varix diameter exceeding 50% of intrahepatic portion of umbilical vein (Figure 3 and 4).<sup>11</sup>

It usually involves the intraabdominal part of the extrahepatic umbilical vein—because this part is the least supported portion of the vessel. The intraamni-

otic portion of the umbilical vein may also be affected. The diameter of normal intraabdominal umbilical vein increases, in a linear fashion, from 3 mm at 15 weeks of gestation to 8 mm at term (Figure 5).<sup>1</sup>

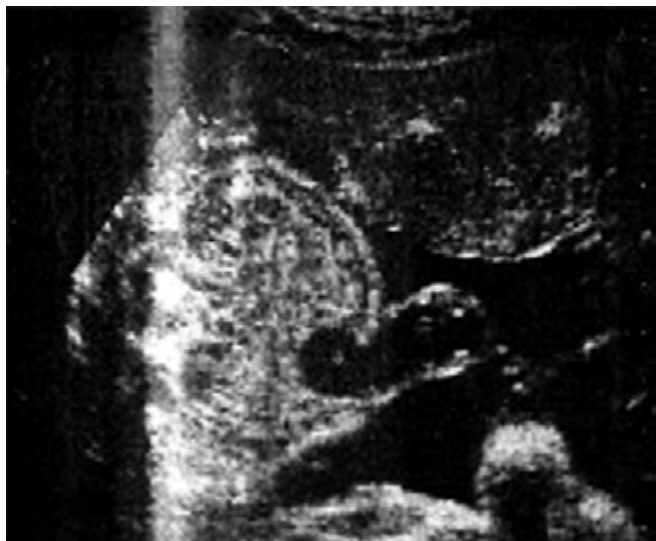An umbilical vein varix is developmental abnormality rather than embryologic.

In several cases, fetuses with umbilical vein varix at 22 to 32 weeks of gestation had normal ultrasound examinations at 16 to 19 weeks (similar to our case).<sup>15</sup> Varix of the intraabdominal umbilical vein, although not necessarily, may be associated with fetal anomalies and thus a detailed sonography is necessary to exclude potential anomalies.

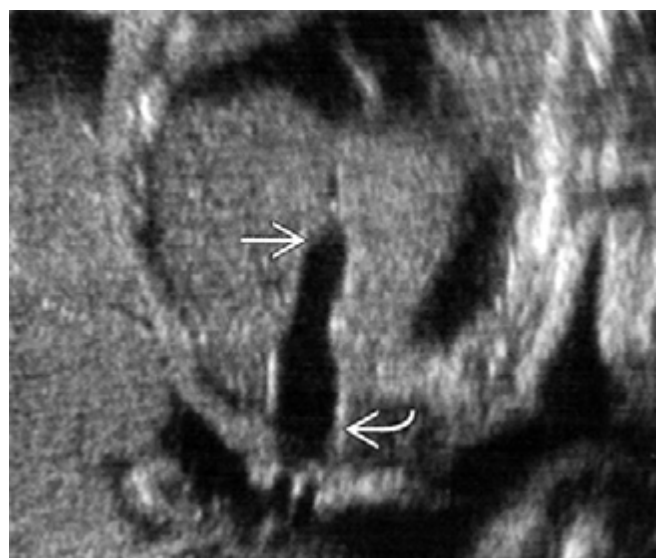
Umbilical vein varix may be the first manifestation of elevated venous pressure; therefore, formal fetal echocardiography should be performed.<sup>1</sup>

Variable outcomes have been reported for intraabdominal umbilical vein varix. Mahony et al. reported that four of nine fetuses with an intraabdominal umbilical vein varix died in utero.<sup>1</sup> However, in another series, all five fetuses were delivered normally at term.<sup>5</sup> Sepulveda et al. reported 10 cases of umbilical vein varix and reviewed 32 cases from the literature: 24% of the fetuses died, 12% had chromosomal abnormality, and 5% acquired hydrops.<sup>11</sup> Of fetal deaths, 3 of 9 had no apparent cause. The remaining 6 fetuses died as a result of karyotypic abnormalities (4), hydrops (1), and structural malformations (1). Of 5 cases of chromosomal abnormality, two fetuses with trisomy 21, two trisomy 18, and one trisomy 9, all had additional sonographically detectable malformations. Of 42 fetuses, 28 (67%) had no prenatal complications and had a normal postnatal outcome.

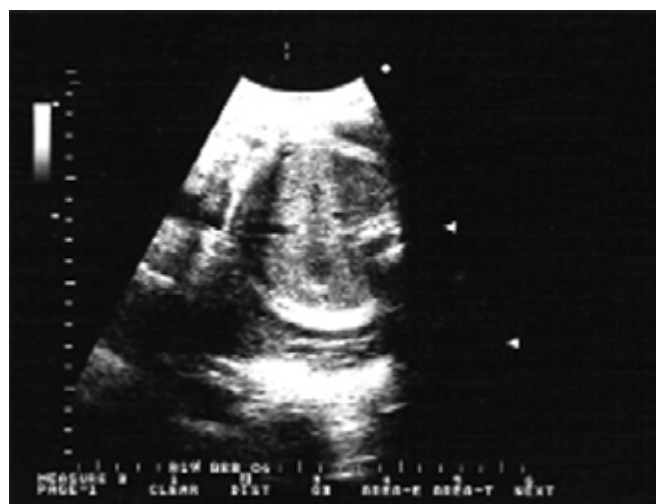In an otherwise normal fetus, the rate and extent of umbilical vein varix thrombosis would determine whether growth restriction,<sup>13</sup> hydrops,<sup>1</sup> or fetal demise<sup>7</sup> occurs. Earlier diagnosis (about second trimester) may correlate with worse outcome. However, in the presence of fetal intraabdominal umbilical vein varix, detailed sonography is mandatory to exclude concomitant fetal anomalies.<sup>14, 15</sup> Karyotyping should be offered when additional fetal abnormalities are detected,<sup>9</sup> and delivery should be induced when lungs are sufficiently mature or in case of any fetal distress.



**Fig 3.** Varix (asterisk) of the umbilical vein.



**Fig 4.** Coronal transabdominal ultrasound shows the increased diameter of the vein (curved arrow) as compared to its intrahepatic portion (arrow).



**Fig 5.** Transverse view of the fetal abdomen at 22 weeks' gestation.

## References

1. Mahony BS, McGahan JP, Nyberg DA, Reisner DP. Varix of the fetal intra-abdominal umbilical vein: comparison with normal. *J Ultrasound Med* 1992;11(2):73-6.
2. Fisk NM, Bower S, Sepulveda W, Garner P, Cameron K, Matthews M, Ridley D, Drysdale K, Wootton R. Fetal telemedicine: interactive transfer of real time ultrasound and video via ISDN for remote consultation. *J Telemed Telecare* 1995;1(1):38-44.
3. Allen SL, Bagnall C, Roberts AB, Teele RL. Thrombosing umbilical vein varix. *J Ultrasound Med* 1998;17(3):189-92.
4. White SP, Kofinas A. Prenatal diagnosis and management of umbilical vein varix of the intra-amniotic portion of the umbilical vein. *J Ultrasound Med* 1994;13(12):992-4.
5. Estroff JA, Benacerraf BR. Fetal umbilical vein varix: sonographic appearance and postnatal outcome. *J Ultrasound Med* 1992;11(3):69-73.
6. Challis D, Trudinger BJ, Moore L, Kennedy DS, Ryan G, Toi A, Seward G, Chitayat D. Intra-abdominal varix of the umbilical vein: Is it an indication for fetal karyotyping? *Am J Obstet Gynecol* 1997;176:s93.
7. Fuster JS, Benasco C, Saad I. Giant dilatation of the umbilical vein. *J Clin Ultrasound* 1985;13(5):363-5.
8. Rizzo G, Arduini D. Prenatal diagnosis of an intra-abdominal ectasia of the umbilical vein with color Doppler ultrasonography. *Ultrasound Obstet Gynecol* 1992;2(1):55-7.
9. Fung TY, Leung TN, Leung TY, Lau TK. Fetal intra-abdominal umbilical vein varix: what is the clinical significance ultrasound obstet Gynecol 2005;25(2):149-54.
10. Babay ZA, Lange IR, Elliott PD, Hwang WS. A case of varix dilatation of the umbilical vein and review of the literature. *Fetal Diagn Ther* 1996 May-Jun;11(3):221-3.
11. Sepulveda W, Mackenna A, Sanchez J, Corral E, Carstens E. Fetal prognosis in varix of the intra-fetal umbilical vein. *J Ultrasound Med* 1998;17(3):171-5.
12. Rahemtullah A, Lieberman E, Benson C, Norton ME. Outcome of pregnancy after prenatal diagnosis of umbilical vein varix. *J Ultrasound Med* 2001;20:135-139.
13. Jeanty P. Fetal and funicular vascular anomalies: identification with prenatal US. *Radiology* 1989;73(2):367-70.
14. Sherer DM, Anyaegbunam A. Prenatal ultrasonographic morphologic assessment of the umbilical cord: a review. Part I. *Obstet Gynecol Surv* 1997;52(8):506-14.
15. Sherer DM, Anyaegbunam A. Prenatal ultrasonographic morphologic assessment of the umbilical cord: a review. Part II. *Obstet Gynecol Surv* 1997 Aug;52(8):515-23. Review.